

## Short communication: An ultrasound study of healthy digital flexor tendons on the metapode in meat calves

Pere M. Parés-Casanova<sup>1</sup>; Júlia Palos-Vila<sup>1</sup>

<sup>1</sup>Department of Animal Science, ETSEA, University of Lleida, Lleida, Catalonia (Spain)

**Keywords:** *Bruna dels Pirineus, Cattle, Digits, Limbs, Ultrasonography*

**Abstract.** *Until now, there has been little investigation of the ultrasonographic appearance of normal anatomical structures of distal limbs and normal dimensions of digital flexor tendons in calves. Studies on the descriptive and topographic anatomy of soft tissue structures in limbs are essential before ultrasonographic signs of injury can be recognized. Ultrasound measurements of the normal size of tendons and ligaments allow recognition of abnormalities. The aim of this study is to provide ultrasonographic measurements of digital flexor tendons in the metapodial region in the meat calf. For this purpose, 44 limbs (right and left forelimbs and right and left hindlimbs) from 11 healthy *Bruna dels Pirineus* and their F1 crosses calves (345–672 days of age and 160.0–331.5 kg carcass weight) were studied post mortem. Cross transverse sections for the structures of three metapodial zones were studied echographically at 7.5 MHz with an ExaGo machine. Although some studies of morphometric measurements by ultrasound in cattle have been reported, no survey of the measurements and proportions of all flexor tendons and ligaments in the metapodial region of calves was found in the literature. The results of this descriptive study allow the establishment of thickness of healthy digital flexor tendons and provide with echographic reference data in young bovines.*

### Introduction

The tendon structures located on the palmar area of the cow are (Berlingieri and Artoni 2011) (International Committee on Veterinary Gross Anatomical Nomenclature 2017):

- tendons of the digital flexor muscles: superficial (*flexor digitorum [digitalis] superficialis*) and deep (*flexor digitorum [digitalis] profundus*);
- *lig. intertendineum*;
- interosseous tendons II and IV (*tendo dorsalis abaxialis* and *tendo plantaris abaxialis*).

The incidence of cattle lameness has been extensively studied, although the prevalence of tendon disorders is unknown (Anderson, Desrochers, and St. Jean 2008), with ultrasonographic studies much less applied than in horses. At the same time few studies have proved the correctness of ultrasonographic inspections of tendons and ligaments by comparing them with necropsy findings. Ultrasound is a safe, easy, non-invasive and effective technique for analysis of soft tissue injuries and currently accessible to any veterinarian clinician (Martínez Martínez 2005) (Gonçalves et al. 2014). Therefore, comprehensive values of ultrasonographic images of digital flexors are required to describe accurately the anatomy of tendons. Moreover, ultrasound measurements of the normal size of tendons and ligaments help to recognize abnormalities.

The purpose of this study was to map the distal limb region in healthy *Bruna dels Pirineus* (Pyrenean

Brown) calves in order to obtain ultrasonographic sectional measurements of flexor tendons and determine if age, sex, carcass weight limb and cutting area have any effect over normal measurements. As provided values are for non-pathologic flexor tendons for this breed, the study can provide the practising veterinarian on the racetrack with reference values, taking age of an animal into account, as this work focuses on structures on calves.

### Materials and methods

A sample of 44 limbs (right and left forelimbs and right and left hindlimbs) from 11 healthy *Bruna dels Pirineus* and their F1 crosses calves (345–672 days of age and 160.0–331.5 kg carcass weight) was collected. The limbs were randomly collected from a slaughterhouse in a commercial slaughterhouse in Catalonia, Spain. The animals were not lame and were clinically healthy according to *ante mortem* abattoir official veterinary inspection and with no previous trimming. Individual information was not possible for samples; therefore, sex and carcass weight for each animal could not be considered, although there were no castrated animals. After slaughter, the limbs were isolated proximal to the carpus and tarsal joints. The samples were transferred to the University of Lleida, Department of Animal Science, where they were stored at –18°C until processing. After thawing at room temperature, the limbs were cleaned in order to eliminate artifacts during ultrasonography (US).

US was done at room temperature. The contact acoustic gel was applied on the surface of the skin of the area to be inspected and on the surface of the probe to be in contact with the skin, in order to avoid the interposition of air between the probe and the

Corresponding author: Correspondence to Pere M. Parés-Casanova, Department of Animal Science, ETSEA, University of Lleida Av. Alcalde Rovira Roure 191. E-25198 Lleida, Catalonia (Spain). E-mail: peremiquelp@ca.udl.cat

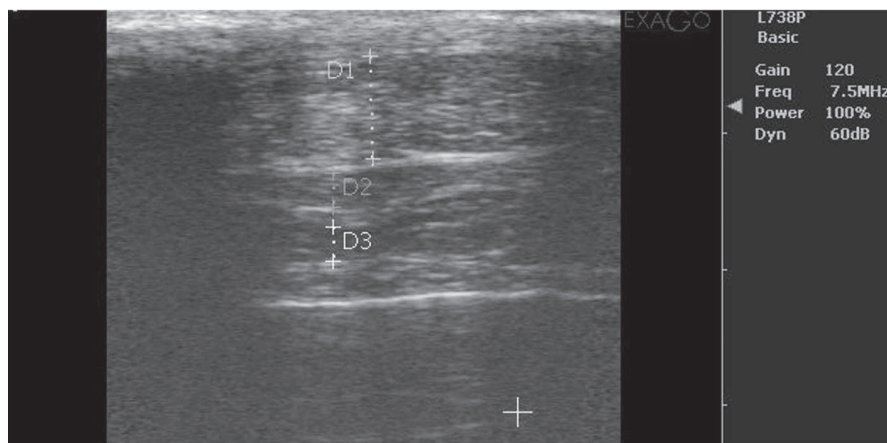


Fig. 1. An echographical transverse view (7.5 MHz) of tendons of the digital flexor muscles: superficial (*flexor digitorum [digitalis] superficialis*) (D1), deep (*flexor digitorum [digitalis] profundus*) (D3) and *lig. intertendineum* (D2).

skin. An US device was equipped with a linear type probe which had a pad adapted. Images were obtained with the US device at 7.5 MHz with an ExaGo machine and transverse images were obtained (Fig. 1). To obtain them, we rotated the probe 90° until it was perpendicular to the transversal axis of the limb. We moved the transducer around the area trying not to press too much anatomical structures to avoid possible artifacts. Measurements were performed on three levels determined by dividing the palmar metapodial region into three equidistant sections, starting from the proximal border of the metacarpal bone (level 1) to the proximal border of the proximal sesamoid bones (level 3). Therefore, tendons/ligaments of calves with different metapodial lengths were measured at an equal ratio. US was performed for both fore and hind limbs and the data were digitally recorded. All ultrasonographic examinations and measurements were performed by the second author.

As some of the values were not normally distributed, non-parametric tests were applied. A one-way NPMANOVA (non-parametric multivariate analysis of variance) analysed differences between genders (6 ♂ and 5 ♀) and fore and hind pairs, and a two-way NPMANOVA analysed differences using “limb” and “level” as factors and 9,999 permutation rounds. For variance tests, Gower’s distances were used as they can handle continuous and categorical variables. Linear multivariate regressions with log-transformed values were performed using “age” and “carcass weight” as independent variables.

The obtained data were statistically analysed with statistical software program PAST v. 2.17c (Hammer, Harper, and Ryan 2001). Differences between means at  $p < 0.05$  were considered significant.

## Results

All parts of the palmar structures were seen on the obtained pictures: skin, subcutaneous tissues, deep digital flexor tendon and superficial digital flexor

tendon, distal accessory ligament and interosseous tendon. The surface of the third metapodial bone was clearly detected as a hyperechoic line.

As there appeared no differences between genders ( $p = 0.075$ ), sexes were pooled for ulterior analysis. There were no regressions neither with age ( $p = 0.204$ , Wilk’s  $\lambda = 0.975$ ,  $F_{2,126} = 1.61$ ) nor carcass weight ( $p = 0.092$ , Wilk’s  $\lambda = 0.963$ ,  $F_{2,126} = 2.42$ ). Limbs presented statistical differences ( $p = 0.006$ ), as well as measurements w according to level ( $p = 0.0001$ ) but their interaction was not significant ( $p = 0.783$ ). Measurements for fore and hindlimbs (but not for right-left pairs) were statistically different ( $p = 0.0023$ ), being those of the latter higher. Table 1 reflects the main descriptive statistics for each tendon and level.

## Discussion

Ultrasound is a widely used technique to evaluate tendon lesions on equids and much less in cattle. There is no report describing the ultrasonographic appearance of distal limbs in the *Bruna dels Pirineus* breed. The most commonly used ultrasound criteria for examining tendon and ligament injuries are the size (area) and echogenicity of tendons. However, in order to apply them in the bovine clinic, we must first know their normal values (Berlingieri and Artoni 2011). So, this work focuses on structures that make up the face of bovine flexor digital tendons, in order to add information about these anatomical structures.

There are few studies on cattle, most researches having been done in equids. In our study, the fore and hind limbs had similar ultrasonographic appearances. The flexor tendons were easily identified as having linear, uniformly intense echogenicity. But measurements for the thoracic and pelvic limbs were different, the latter being bigger, something expected as hindlimbs have biomechanics more stressed during locomotion. Interestingly, in Nellore and Girolando cattle, there have been found no significant differences when comparing thoracic/pelvic limbs at any age

**Table 1.** Morphometric measurements (thickness) for the two flexor tendons and ligament for 44 ultrasonographed limbs from meat calves belonging to *Bruna dels Pirineus* breed and their F1 crosses.

## A/ Forelimbs\*

	Proximal level		Middle level		Distal level	
	FDS	FDP	FDS	FDP	FDS	FDP
Minimal value	2.6	4.2	3.7	4.6	2.5	3.6
Maximal value	9.4	11.1	8.5	12.5	5.9	14.1
Mean	5.6	8.0	6.1	7.4	3.9	8.9
Standard deviation	1.865	1.920	1.280	2.010	0.863	2.936
Coefficient of variation	33.1	24.0	21.0	27.0	22.0	32.8

## B/ Hindlimbs\*

	Proximal level		Middle level		Distal level	
	FDS	FDP	FDS	FDP	FDS	FDP
Minimal value	4.0	3.0	4.2	3.1	2.7	3.8
Maximal value	11.6	14.4	9.2	12.2	9.0	17.5
Mean	7.5	8.8	7.1	7.6	4.5	9.3
Standard deviation	2.340	2.479	1.411	2.308	1.594	3.240
Coefficient of variation	31.0	28.0	19.9	30.3	35.2	35.0

\*Measurement in mm, except for coefficient of variation, in %. Thickness is expressed as palmo/planto-dorsal measurement. Results for fore and hindlimbs are presented separately, these latter being higher. FDS: *Flexor digitorum superficialis*; FDP: *Flexor digitorum profundus*.

(Gonçalves et al. 2014). Differences appear between proximal, middle and distal sections.

Although some studies of morphometric measurements by ultrasound in cattle have been reported, only a survey of measurements and proportions of all flexor tendons in the metapodial region of Nellore and Girolando breed was found in the literature (Gonçalves et al. 2014). Values for these breeds are clearly lower than those found by us. We think that differences in tendon/ligament dimensions could be due to breed, age, body weight, height, exercise programme and accuracy of ultrasound equipment. Thus, more information on variations for more breeds would be needed.

### Conclusions

Ultrasonographic morphometric measurements (thickness) for flexors, at proximal, middle and dis-

tal levels, for calves belonging to *Bruna dels Pirineus* breed and their F1 crosses are offered. The values were different between thoracic and pelvic limbs, the latter being bigger. Differences also appear between proximal, middle and distal sections. The results of this study establish important ultrasonographic reference data of normal structures of distal limbs and normal dimensions of flexor tendons in meat calves for use in clinical practice.

### Conflict of interest

The authors declare that there are no competing interests regarding the publication of this paper. There were no funders in study design, data collection and analysis, decision to publish, or preparation of the manuscript. The *postmortem* use of non-edible parts did not require an approval from the Ethics Committee.

### References

- Anderson, D.E., A. Desrochers, and G. St. Jean. 2008. "Management of Tendon Disorders in Cattle." *Veterinary Clinics of North America - Food Animal Practice* 24(3):551–66.
- Berlingieri, M.A., and S.M.B. Artoni. 2011. "Morphological Aspects of Flexor Face of Digits of Crossbred Nelore Heifers." *Ars Veterinaria* 27(2): 66–72.
- Gonçalves, P.V.R. et al. 2014. "Ultrasonography of the Distal Limbs in Nellore and Girolando Calves 8 to 12 Months of Age." *BMC Veterinary Research* 10.
- Hammer, Ø., D.A.T. Harper, and P.D. Ryan. 2001. "PAST v. 2.17c." *Palaeontologia Electronica* 4(1): 1–229.
- International Committee on Veterinary Gross Anatomical Nomenclature. 2017. *Nomina Anatomica Veterinaria*. World Association of Veterinary Anatomist.
- Martínez Martínez, M. de los Llanos. 2005. "Estudio Eco-gráfico (Ecogenidad y Área) de Los Tendones Flexores de La Extremidad Anterior Del Caballo Pura Raza Español." Universidad de Murcia. <http://nadir.uc3m.es/alejandro/phd/thesisFinal.pdf>.

Received 7 October 2020

Accepted 24 November 2020